

## Conventional biotyping revealed *Mycoplasma* and antimicrobial resistant *Escherichia coli* and *Salmonella* isolates during disease outbreak in broiler farms and hatcheries in Leyte, Philippines

Eugene B. Lañada<sup>1\*</sup>, Harvie P. Portugaliza<sup>1</sup>, Analyn I. Blanza<sup>2</sup>, Mercy Cheryll C. Espejo<sup>3</sup>, Ma. Delia A. Pagente<sup>1</sup>

### ABSTRACT

Received: 08 January 2021 | Accepted: 14 January 2022

A respiratory disease outbreak investigation was carried out from October to December 2015 in three broiler farms and two hatcheries in Leyte. Three- to seven-day-old chicks from farms were initially brought to CVM diagnostic laboratory for necropsy and microbial analyses. Subsequent visits to hatcheries and farms were made for random swabbing and sampling of physical facilities, equipment, vehicle, unhatched eggs, 18-day old eggs, eggshells, and day-old chicks. Chick necropsy, embryo examination, and bacteriological method for *Mycoplasma*, *Escherichia coli*, *Salmonella*, and *Aspergillus* were performed. Antimicrobial sensitivity testing was conducted for *Salmonella* and *E. coli* isolates. The main clinical sign observed in chicks was dyspnea. Necropsy revealed consistent bilateral fibrinous airsacculitis and perihepatitis with few cases of pericarditis, wherein sampled organs consistently showed the presence of *E. coli*. Out of 83 samples collected, 19 (22.89%) *Salmonella*, 40 (48.19%) *E. coli*, and no *Aspergillus* were isolated. Most *E. coli* were isolated from chick embryos and necropsied chickens, while *Salmonella* isolates were mostly from the environment. *Mycoplasma* was isolated from 63.64% (7/11) of sampled lungs, air sacs, and liver from unhatched embryos (100%), 18-day old embryos (50%), and day-old chicks (33.33%). The majority of *Salmonella* and *E. coli* isolates showed multidrug resistance against amoxicillin, chloramphenicol, erythromycin, trimethoprim/sulfamethoxazole (TMPS), and tetracycline. Few isolates were sensitive to ciprofloxacin. Our results should raise awareness on the occurrence of antimicrobial-resistant *E. coli* and *Salmonella*, and coinfection with *Mycoplasma* among broilers in Leyte. Therefore, proper selection and usage of antibiotics should be advocated in all poultry farms.

**Keywords:** Antimicrobial-resistant, *E. coli*, *Mycoplasma*, Poultry outbreak, *Salmonella*

<sup>1</sup>College of Veterinary Medicine, Visayas State University

<sup>2</sup>Chicken Essentials Philippines, Incorporated, Ormoc City, Philippines

<sup>3</sup>Bureau of Animal Industry Regional Office 7, Cebu City, Philippines

\*Corresponding Author. Address: College of Veterinary Medicine, Visayas State University; Email: eblanada@vsu.edu.ph

## INTRODUCTION

In the Philippines, the industry of intensive broiler production through contract growing flourishes over the years to achieve the increasing demand for broiler meat in the market (Chang 2007). However, as broiler production becomes intensive, different broiler diseases virtually emerge (Talebiyan et al 2014). *Mycoplasma*, *Escherichia coli*, and *Salmonella* are the top three most common bacterial diseases in broilers, causing economic drawbacks (Lutful Kabir 2010, Pourbakhsh et al 2010).

Avian mycoplasmosis is caused by *Mycoplasma gallisepticum* and *M. synoviae* producing chronic respiratory disease (CRD) and infectious synovitis, respectively. *Mycoplasma* is transmitted through eggs and disseminated in the hatchery (Khalifa et al 2013). Usually, flock infected with *Mycoplasma* experience a low hatching rate, diminished day-old chick quality, and stunted broiler growth. Moreover, a broiler infected with *Mycoplasma* has shown to be more sensitive to *E. coli* infection (Stipkovits et al 2012).

The serogroups of avian pathogenic *E. coli* (APEC) are principally associated with extraintestinal infections, damaging the respiratory tract and other vital organs in the later stage. APEC causes septicemia, airsacculitis, and pericarditis, enhanced by *Mycoplasma*, viral agent, and stressful environment (Blanco et al 1998). Similar to *Mycoplasma*, APEC leads to embryonic mortality and significant morbidity and mortality among day-old to 3-week-old chickens (Daho-Moulin and Fairbrother 1999).

Avian salmonellosis is caused by the host-adapted *Salmonella* biovar gallinarum and pullorum, and the non-host adapted but highly invasive *Salmonella* serotypes enteritidis and typhimurium. *Salmonella* are both transmitted vertically (ie, from infected hens to the eggs) and horizontally (ie, through feces), resulting in widespread environmental contamination (Lutful Kabir 2010). Aside from its effect on chicken egg production and broiler's health, it is well accepted that broilers are a significant reservoir for human salmonellosis (Limawongpranee et al 1999).

Massive broiler deaths due to *Mycoplasma*, APEC, and *Salmonella* happen when birds' immune system is down due to stressful environments or other predisposing factors (eg, vaccination) that succumb to immunocompromised birds (Kleven 1998). In addition, mixed infections or in association with a viral agent create a synergistic effect that commonly results in high mortality (Landman 2014, Springer et al 1974). In the Philippines, an outbreak of enterotoxigenic *E. coli* causing diarrhea in broilers was first demonstrated in Southern Tagalog by Joya et al (1990). Also, approximately 75,000 cases of avian mycoplasmosis were reported in 1992 by the Bureau of Animal Industry (Sato 1996). On the other hand, *Salmonella* was mainly reported from chicken meat and eggs (Santos et al 2020, Manguiat and Fang 2013, Balala et al 2006).

Like other developing countries, securing disease-free chicks is difficult in the current Philippine scenario, possibly due to economic barriers and the lack of existing infrastructure and technology (Morrow 2014). Hence, the use of antimicrobials becomes the vanguard of controlling and treating chicken diseases even without the proper diagnosis (Pourbakhsh et al 2010). Unfortunately, due to the indiscriminate usage of antimicrobials, there were already reports of antimicrobial-resistant (AMR) *E. coli* and *Salmonella* in the Philippines (Jiao et al 2007) and AMR *Mycoplasma* in other countries (Morrow 2014).

### Conventional biotyping revealed *Mycoplasma* and antimicrobial resistant

In this paper, we demonstrate the occurrence of *Mycoplasma* colonies from chick embryo and day-old chick, and AMR *E. coli* and *Salmonella* from the chick and environment during an outbreak investigation in Leyte, Philippines. We further describe the clinicopathological findings and emphasize the importance of conducting antimicrobial sensitivity tests at the height of broiler disease outbreaks.

## MATERIALS AND METHODS

### *Description of the Study Area*

An outbreak investigation was conducted in three commercial broiler farms located in the municipality of Leyte (11°22'N 124°29'E) and Kananga (11°11'N 124°34'E) and the city of Baybay (10°41'N 124°48'E) (Figure 1). Two of the farms were tunnel-ventilated with a flock capacity of 30,000 to 40,000 birds, while one farm followed a conventional practice with a flock capacity of 20,000 to 30,000 birds. In addition, hatcheries in Ormoc (11°01'N 124°37'E) and Tacloban Cities (11°14'N 125°00'E) were sampled after the three farms experienced high mortality on the first 14 days of growth. The two hatcheries supplied the day-old chicks to the three broiler farms.

### *Chronology of Outbreak Investigation and Sample Collection*

In October 2015, a total of 20 heads of 3-to-7-day-old chicks from broiler farms were brought to CVM diagnostic laboratory. Necropsy of apparently healthy and diseased birds with early and advanced clinical signs was performed following the procedure described by CEVA (2007). The organs with lesions were sampled for fungal and bacterial analyses. In addition, presenting clinical signs and gross lesions were recorded. The disease history and other relevant information were derived through interviews of farm owners.

A one-time visit to hatcheries and farms was made in December 2015. Random sampling of hatcheries was carried out in physical facilities, equipment, and vehicle. These involved the chick van, floor, and fan at receiving area, floor and air-condition of egg rooms, fumigation room, incubators, egg tray, drainage, vaccinator, and vaccine. In addition, 18-day-old eggs, chick embryos from unhatched eggs, day-old chicks, eggshells, and infertile eggs (“penoy”) were randomly collected and analyzed. The hatching rate records were also gathered. Farm sampling was also conducted on a similar date. The team randomly sampled the on-site broiler chicks, feeds, water, floor, feeder, and waterer.

### *Isolation and Identification of *E. coli**

The sampled organs and swabs in buffered peptone water (BPW) were initially incubated aerobically for 24h at 37°C. Bacterial inoculum from the BPW was streaked on sheep blood agar and incubated for 24h at 37°C. The colonies from blood agar were then classified into gram-positive and gram-negative through the gram staining method. Isolated colonies were streaked into three selective and differential media: Xylose Lysine Deoxycholate Agar (XLD agar), Eosin Methylene Blue agar (EMB agar), and MacConkey agar. The morphology of the colonies was

noted for typical *E. coli* characteristics after 24h of aerobic incubation at 37°C. *E. coli* colonies appeared yellow in XLD agar, bluish metallic in EMB agar, and reddish-pink in MacConkey agar. Biochemical analyses conducted to confirm *E. coli* phenotypically included IMViC test (indole test [+], methyl red test [+], Voges-Proskauer test [-] and citrate test [-]), triple sugar iron (TSI) slant reaction (K/A with gas), motility test (brush-like), ornithine decarboxylase test (-), and selected carbohydrate fermentation tests (ie, dulcitol, glucose, maltose and rhamnose) (Timoney et al 1988).

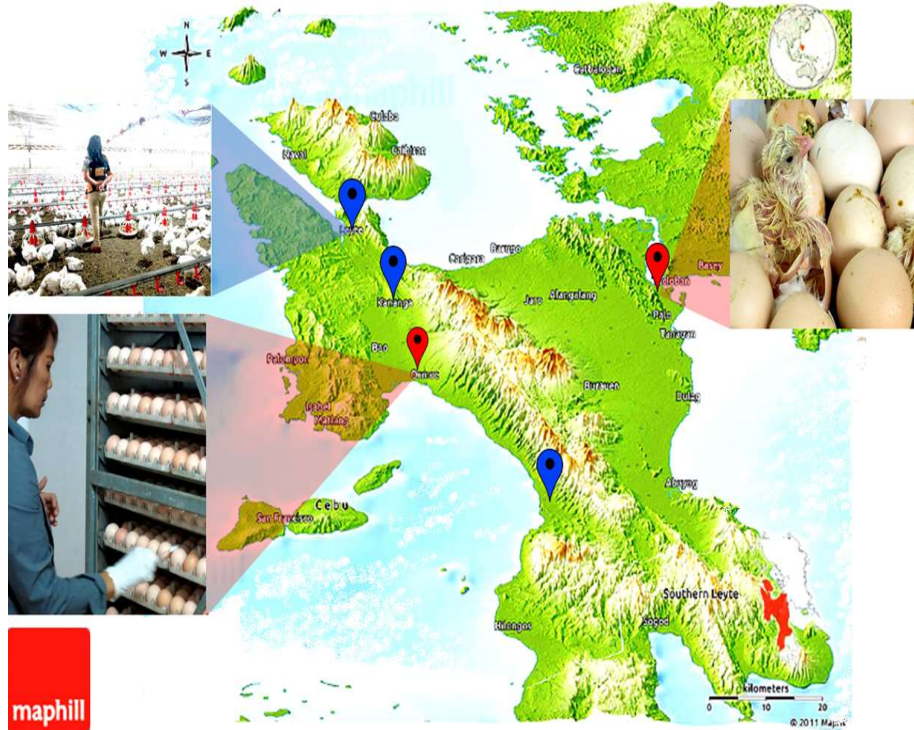

Figure 1. The map of Leyte Island showing the outbreak investigation sites. Red pins indicate the hatcheries, while the blue pins were the broiler farms. (Map source: <http://www.maphill.com/>)

### Isolation and Identification of *Salmonella*

The collected samples were pre-enriched in BPW for 24h at 37°C, and one mL aliquot was transferred into tetrathionate broth for 48h enrichment at 42°C. A loop of inoculum was streaked on the XLD agar and incubated for 24-48h at 37°C. After incubation, the plate was examined for colonies with blackened centers which are typical for *Salmonella*. The isolated colonies were then streaked on EMB agar and MacConkey agar to observe amber pink and colorless colonies, respectively. The biochemical analyses conducted for further biotyping were IMViC test (Indole [-], methyl red [+]; Voges-Proskauer [-] and citrate [+]) TSI slant reaction (K/A with gas and blackening), motility test (-/+), ornithine decarboxylase test (-), and carbohydrate fermentation tests (ie, dulcitol, glucose, maltose, and rhamnose) (Timoney et al 1988).

Conventional biotyping revealed *Mycoplasma* and antimicrobial resistant

### **Aspergillus Isolation**

The collected samples were inoculated in potato dextrose agar (PDA) and Sabaroud dextrose agar. The plates were incubated for five days at 26°C. The gross morphology of fungal colonies was recorded, and the microscopic morphology was identified using a lactophenol blue stain (Timoney et al 1988).

### **Mycoplasma Isolation**

*Mycoplasma* spp. from embryos was isolated using a *Mycoplasma* Agar Base (Pleuropneumonia-like organism [PPLO] agar) with 10% horse serum as a growth stimulant. The Swab-inoculation technique was carried out in the liver, air sacs, and lungs, where lesions were observed. The plates were incubated in an anaerobic environment for 14 days at 37°C. After incubation, the colonies were observed under the microscope (40x magnification) for a “fried egg” appearance (Zimbro et al 2009, Freundt 1983).

### **Antimicrobial Sensitivity Testing**

The antimicrobial susceptibility pattern or antibiogram of *E. coli* and *Salmonella* isolates was determined using the disk diffusion method or Kirby-Bauer (K-B) test on a Mueller-Hinton agar plate incubated at 37°C for 16-18h (Coyle 2005). Six commercially available antibiotic discs (Bioanalyse®) were tested; these were 25µg amoxicillin, 30µg chloramphenicol, 5µg ciprofloxacin, 15µg erythromycin, 1.25/23.75µg trimethoprim/sulfamethoxazole, and 30µg tetracycline. Bacterial isolates were classified as sensitive (S), intermediate (I), and resistant (R) to antibiotics based on the diameter of the zone of inhibition. The categorization was based on the published data of the Clinical and Laboratory Standards Institute (CLSI) (2013) and the British Society for Antimicrobial Chemotherapy (BSAC) (Andrews 2009) for the Enterobacteriaceae family (Table 1).

Table 1. Zone of inhibition breakpoints (mm) of the selected antimicrobials used to test the susceptibility of *E. coli* and *Salmonella* isolate

Antimicrobial Agent	Potency	Zone Diameters in mm		
		R	I	S
Amoxicillin	25µg	≤11	12–14	≥15
Chloramphenicol	30µg	≤12	13-17	≥18
Ciprofloxacin	5µg	≤16	17-19	≥20
Erythromycin	15µg	≤13	14-17	≥18
Trimethoprim/Sulfamethoxazole	1.25/23.75µg	≤10	11-15	≥16
Tetracycline	30µg	≤11	12-14	≥15

R= Resistant, I = Intermediate, S= Sensitive  
Source: CLSI, 2013; Andrews, 2009

## **RESULTS AND DISCUSSION**

Interviews indicated that broiler farms were operational for at least three years under a contract growing company. The broiler chicks were vaccinated against infectious bronchitis on day 1, Newcastle disease on days 7 and 15, and infectious



bursal disease on day 15. The antibiotics administered during outbreaks were amoxicillin and doxycycline. However, a remarkable mortality rate remained on day 2, reaching about 60% upon harvest in one of the farms, which is 15-fold higher than the typical mortality rate of 4% in broiler farms under the Philippine conditions (BMSMED 2009). Gasping or dyspnea was the typical clinical sign observed by owners and was confirmed upon examination by the veterinarian.

Necropsy of chicks presented no apparent gross lesion in the infraorbital sinus and trachea. However, all sampled chicks showed thickened and opaque air sacs with adherent caseous deposits (Figure 1). The necropsy also showed retention of the yolk sac and fibrinous exudates in the lungs, the surface of the liver, and the pericardial sac. The chick embryos from unhatched eggs showed fibrinous inflammation of the airsacs, liver, and pericardial sacs. Also, few 18-day old chickens manifested fibrinous exudates in similar organs. Fibrinous exudates suggested severe acute vascular injury attributed to bacterial endotoxins. These lesions were typical for avian pathogenic *E. coli* of O serogroups and *Mycoplasma* infection (Blanco 1998, Kleven 1998). Although we cannot confirm any viral association since the tests were unavailable, the lesions presented were least likely to be a clinical viral disease based on lesions or possibly a subclinical infection in synergy with the bacterial agent.

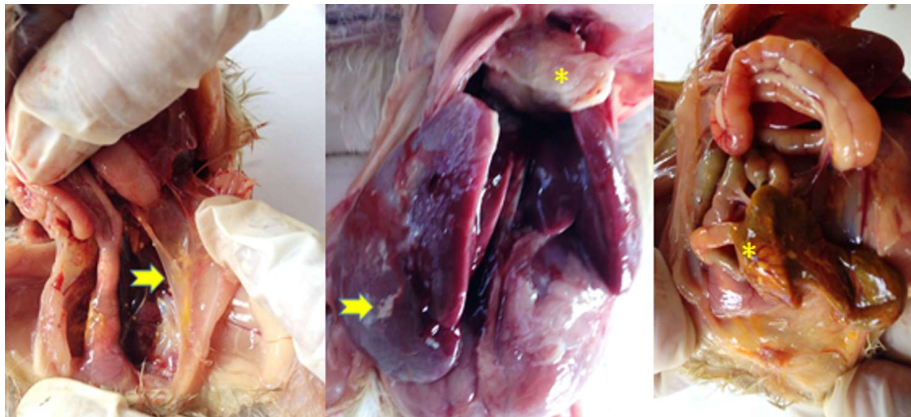

Figure 2. Gross lesions of examined 7-day old broiler chicks showed fibrinous airsacculitis (left arrow), fibrinous perihepatitis (middle arrow) and pericarditis (middle \*), and yolk sac retention (right \*)

Bacterial culture and identification in sampled chicks, egg embryos, and environment showed *E. coli*, *Salmonella*, and *Mycoplasma* (Table 2). *Aspergillus* was not isolated from the necropsied chicks, eggs, embryos, and the environment. It should be noted that the identification was based only on the results of conventional biotyping; hence, the determination of species and serotypes of some bacteria was not possible. Furthermore, tests for viral agents were not available.

Almost half (48.18%) of the samples were positive for *E. coli*, and the majority were isolated from air sacs, lungs, liver, kidney, and heart of unhealthy chicks and embryos. In addition, *E. coli* was isolated from the eggshells in the incubator and the floor of the egg room and chick van. Our results suggested that the isolated *E. coli* could be one of the APEC serogroups, as evident by the clinical presentation and

Conventional biotyping revealed *Mycoplasma* and antimicrobial resistant

typical extraintestinal lesions. Biochemically, all *E. coli* isolates from chicks and embryos were dulcitol fermenters, which is an indicator for an APEC isolate (Daho-Moulin and Fairbrother 1999).

Also, we were able to isolate *Mycoplasma* spp. (Figure 2) from the lesioned organs of embryos of 18-day old and unhatched eggs and day-old chicks. Coinfections with *E. coli* were also common among samples that tested positive for *Mycoplasma* spp. All of the unhatched embryos at the late developmental stage showed severe fibrinous and caseous deposits on airsacs, liver, and heart. This finding may have contributed to the relatively lower average hatching rate than 85% standard (Copur et al 2010) in Hatchery A (82.73%) and Hatchery B (78.72%) from September to November 2015. In many studies, chicken infected with *Mycoplasma* demonstrated a faster spread of *E. coli* infection, resulting in septicemia as evident by polyserositis, airsacculitis, pericarditis, and perihepatitis (Stipkovits et al 2012).

*Salmonella* was also isolated from 19 of the 83 samples (22.89%), in which many positive samples were from the equipment and facilities of hatcheries and farms. The contamination of *Salmonella* in the environment is expected since a massive amount of the bacteria are shed through feces (Lutful Kabir 2010). In young broilers, *Salmonella* isolates were usually from the liver showing congestion and perihepatitis. This finding agrees with the reports stating that the liver serves as an important multiplication site for *Salmonella* (Foley et al 2013).

Table 2. The proportion of *E. coli*, *Salmonella*, and *Mycoplasma* isolated from broiler chicks, eggs, and environment during the outbreak investigation

Sample	N	<i>E. coli</i>		<i>Salmonella</i>		<i>*Mycoplasma</i>		<i>Aspergillus</i>	
		n	%	n	%	n/N	%	N	%
Farm									
3-7 Day-old Chick	21	20	95.24	1	10	-	-	0	0
Facility and Equipment	4	0	0	2	50	-	-	0	0
Hatchery									
18-day old Eggs	12	8	66.67	1	8.33	2/4	50	0	0
Unhatched Eggs	8	5	62.50	1	12.5	4/4	100	0	0
Egg Shells	10	0	0	0	0			0	0
Day-old Chick	6	3	50	4	66.67	1/3	33.33	0	0
Facility, Equipment, and Vehicle	22	4	18.18	10	45.45	-		0	0
Total	83	40	48.19	19	22.89	7/11	63.64	0	0

\*Only selected samples were cultured for *Mycoplasma* colonies.  
N= total sample; n= positive sample

The antibiogram pattern of the isolated *E. coli* and *Salmonella* from broiler chicks, embryos, and environment during the outbreak is shown in Figure 3. All *E. coli* isolates showed 100% resistance to amoxicillin. The majority were also resistant to TMPS (95.45%), erythromycin (95.45%), tetracycline (85%), chloramphenicol (70%), and ciprofloxacin (63.64%). There were very few isolates that were susceptible to ciprofloxacin, tetracycline, and chloramphenicol. On the other hand, *Salmonella* exhibited 100% resistance to amoxicillin, tetracycline, and erythromycin. Of the *Salmonella* isolates, 76.92% were susceptible to ciprofloxacin. However, a high rate of resistance was observed against TMPS (92.31%) and chloramphenicol (84.62). It is alarming to note that all isolates were resistant to at least one antibiotics

(Figure 4), suggesting the presence of multidrug-resistant (MDR) *E. coli* and *Salmonella* among broiler farms in Leyte. Of note, a bacterium is classified as MDR if it is resistant to three or more classes of antibacterial agents based on results of in vitro antimicrobial susceptibility assay (Magiorakos et al 2012). The antimicrobial sensitivity test may also explain the poor recovery rate and the continued manifestation of clinical signs even after amoxicillin and doxycycline administrations. MDR *E. coli* and *Salmonella* from chicken were also reported in Manila and Laguna (Manguiat and Fang 2013, Jiao et al 2007); however, these were not from clinical cases.

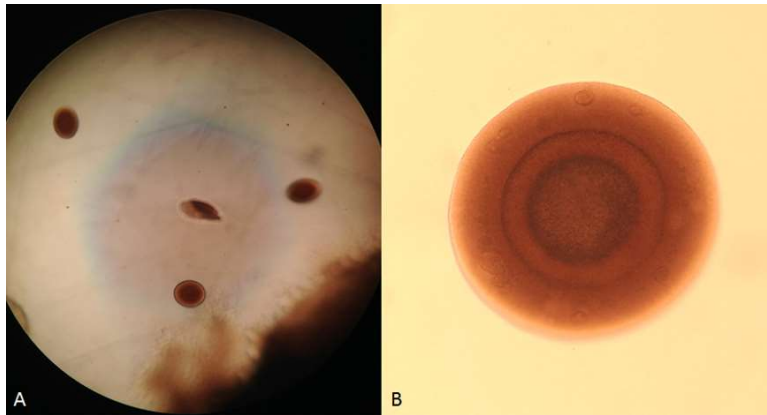


Figure 3. *Mycoplasma* colonies on a *Mycoplasma* Agar Base enriched with 10% horse serum showing the typical “fried egg” appearance. (A=40x magnification; B=Magnified colony at 100x)

Selecting an antibiotic at the height of any disease outbreak is vital to control the infection. Based on the in vitro antibiotic sensitivity testing conducted against the isolated organisms, the fluoroquinolone group of antibiotics showed a likelihood of therapeutic success. Furthermore, after treating the broiler chicks with enrofloxacin, the farm owners reported significant improvement in the daily mortality rate of chicks. In Mexico, the use of enrofloxacin in broilers showed remarkable clinical efficacy against *E. coli* and *Mycoplasma* mixed infection (Sumano et al 1998). Conversely, the inability of amoxicillin and doxycycline in minimizing the death of chicks during the disease outbreak was confirmed by the in vitro results showing antimicrobial resistance.

The high broiler mortality rate experienced by the farmers suggested the involvement of multiple factors at the level of the farm, hatchery, and breeders. The three organisms are transmitted vertically; therefore, it is assumed that the infection was derived from breeders. Hatcheries may have a significant role in spreading the pathogens since poor hygiene in handling eggs and day-old chicks was observed during our visits. Also, infected breeders may have been the source of infected embryos, producing weak day-old chicks that were vulnerable to stress. Once a stressful environment sets in, these bacteria will multiply, resulting in high mortality rates. Hence, effective medication and vaccination are vital in controlling these pathogens (Kleven 1998). Appropriate flock-health management system and biosecurity program in the breeder farms and hatchery facility should be in place to prevent and control disease outbreaks in broiler farms.



Conventional biotyping revealed *Mycoplasma* and antimicrobial resistant

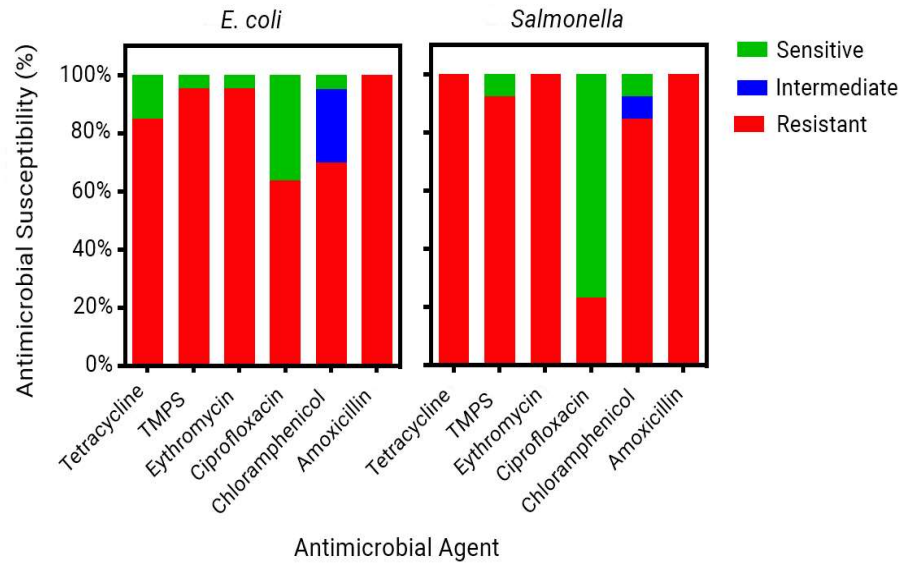


Figure 3. The proportion of resistant, intermediate, and sensitive *E. coli* and *Salmonella* isolates from hatchery and broiler farm samples

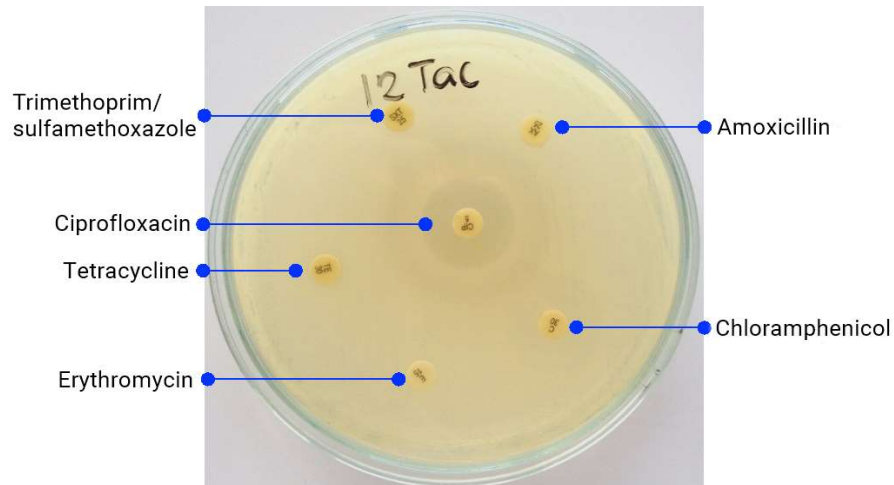


Figure 4. Disc diffusion antibiotic sensitivity testing of one of the *E. coli* isolates showing the zone of inhibition exhibited by ciprofloxacin (5µg CIP) and resistance against amoxicillin (25µg AX), chloramphenicol (30µg C), erythromycin (15µg E), µg trimethoprim/sulfamethoxazole (1.25/23.75µg SXT), and tetracycline (30µg TE)

## CONCLUSION

Through bacteriological method, we demonstrated the presence of *Mycoplasma* and antimicrobial-resistant *E. coli* and *Salmonella* during broiler disease outbreak

investigation in Leyte, Philippines. Alarmingly, all *E. coli* and *Salmonella* isolates were resistant to at least one antibiotics. The clinicopathological presentation of the affected broiler principally involved dyspnea, airsacculitis, pericarditis, and perihepatitis. In vitro antibiotic sensitivity testing showed a high likelihood of therapeutic success using the fluoroquinolone group and was evident in vivo as it minimized the daily chick mortality rate. Therefore, proper selection and usage of antibiotics should be advocated in all poultry farms.

## ACKNOWLEDGMENTS

We acknowledge the cooperation of the involved farm owners, hatchery owners, and the contract growing company.

## REFERENCES

- Andrews JM. 2009. BSAC standardized disc susceptibility testing method (version 8). *Journal of Antimicrobial Chemotherapy* 64(3):454-489
- Balala LM, Rovira HG, Vizmanos MC, Bernardo FM & Divina BP. 2006. Isolation, serologic identification and antibiotic sensitivity testing of *Salmonella* spp. in chickens. *Philippine Journal of Veterinary Medicine* 43(2):63-70
- Blanco JE, Blanco M, Mora A, Jansen WH, García V, Vázquez ML & Blanco J. 1998. Serotypes of *Escherichia coli* isolated from septicaemic chickens in Galicia (Northwest Spain). *Veterinary Microbiology* 61(3):229-235
- CEVA Sante Animale. 2007. Necropsy broilers and chickens. La Ballastière, BP 126, 33501, Libourne Cedex, Paris, France
- Chang HS. 2007. Overview of the world broiler industry: implications for the Philippines. *Asian Journal of Agriculture and Development* 4(2):67-82
- Clinical and Laboratory Standards Institute (CLSI). 2013. Performance standards for antimicrobial susceptibility testing. Twenty-third informational supplement. CLSI document M100-S23. Clinical and Laboratory Standards Institute, Wayne, Pennsylvania
- Copur G, Arslan M, Duru M, Baylan M, Canogullari S & Aksan E. 2010. Use of oregano (*Origanum onites* L.) essential oil as hatching egg disinfectant. *African Journal of Biotechnology* 9(17):2531-2538
- Cortés CR, Isaías GT, Cuello CL, Flores JMV, Anderson RC & Campos CE. 2004. Bacterial isolation rate from fertile eggs, hatching eggs, and neonatal broilers with yolk sac infection. *Revista Latinoamericana de Microbiología* 46(1-2):12-16
- Coyle MB. 2005. Manual of antimicrobial susceptibility testing. American Society for Microbiology, Washington, DC
- Bureau of Micro, Small and Medium Enterprise Development (BMSMED). 2009. Starting a Business – Poultry Raising. Department of Trade and Industry, Philippines
- Dho-Moulin M and Fairbrother JM. 1999. Avian pathogenic *Escherichia coli* (APEC). *Veterinary Research* 30(2):299-316
- Foley SL, Johnson TJ, Ricke SC, Nayak R & Danzeisen J. 2013. Salmonella pathogenicity and host adaptation in chicken-associated serovars. *Microbiology and Molecular Biology Reviews* 77(4):582-607

Conventional biotyping revealed *Mycoplasma* and antimicrobial resistant

- Freundt EA. 1983. Culture media for classic mycoplasmas. *Methods in Mycoplasmaology* 1:127-135
- Jiao SC, Fami RM, Pedernal VA & Cabrera EC. 2007. Prevalence of multiple drug-resistant *Escherichia coli* from the chicken, pig and Nile tilapia (*Oreochromis niloticus*) intestines sold in wet markets in Manila [Philippines] and the conjugative transferability of the resistance. *Philippine Agricultural Scientist* 90(1):64-70
- Khalifa KA, Sidahmed Abdelrahim E, Badwi M & Mohamed AM. 2013. Isolation and molecular characterization of *Mycoplasma gallisepticum* and *Mycoplasma synoviae* in chickens in Sudan. *Journal of Veterinary Medicine* 2013(208026):1-4
- Kleven SH. 1998. Mycoplasmas in the etiology of multifactorial respiratory disease. *Poultry Science* 77(8):1146-1149
- Landman WJ. 2014. Is *Mycoplasma synoviae* outrunning *Mycoplasma gallisepticum*? A viewpoint from the Netherlands. *Avian Pathology* 43(1):2-8
- Limawongpranee S, Hayashidani H, Tomomitsu Okatani A, Ono K, Hirota C, Kaneko KI & Ogawa M. 1999. Prevalence and persistence of salmonella in broiler chicken flocks. *Journal of Veterinary Medical Science* 61(3):255-259
- Lutful Kabir SM. 2010. Avian colibacillosis and salmonellosis: a closer look at epidemiology, pathogenesis, diagnosis, control and public health concerns. *International Journal of Environmental Research and Public Health* 7:89-114
- Magiorakos AP, Srinivasan A, Carey RB, Carmeli Y, Falagas ME, Giske CG, Harbarth S, Hindler JF, Kahlmeter G, Olsson-Liljequist B & Paterson DL. 2012. Multidrug-resistant, extensively drug-resistant and pandrug-resistant bacteria: an international expert proposal for interim standard definitions for acquired resistance. *Clinical Microbiology and Infection* 18(3):268-281
- Manguiat LS and Fang T.J. 2013. Microbiological quality of chicken-and pork-based street-vended foods from Taichung, Taiwan, and Laguna, Philippines. *Food Microbiology* 36(1):57-62
- Morrow CJ. 2014. Rational reduction in antibiotic dependence by total mycoplasma control. *Proceedings of the Sixty-Third Western Poultry Disease Conference*, Puerto Vallarta, Jalisco, Mexico
- Pourbakhsh SA, Shokri GR, Banani M, Elhamnia F & Ashtari AB. 2010. Detection of *Mycoplasma synoviae* infection in broiler breeder farms of Tehran province using PCR and culture methods. *Archives of Razi Institute* 65(2):75-81
- Santos PDM, Widmer KW & Rivera WL. 2020. PCR-based detection and serovar identification of salmonella in retail meat collected from wet markets in Metro Manila, Philippines. *PLoS One* 15(9):0239457
- Sato S. 1996. Avian mycoplasmosis in Asia. *Revue Scientifique et Technique (International Office of Epizootics)* 15(4):1555-1567
- Stipkovits L, Glavits R, Palfi V, Beres A, Egyed L, Denes B, Somogyi M & Szathmary S. 2012. Pathologic lesions caused by coinfection of *Mycoplasma gallisepticum* and H3N8 low pathogenic avian influenza virus in chickens. *Veterinary Pathology* 49(2):273-283
- Sumano LH, Ocampo CL, Brumbaugh GW & Lizarraga RE. 1998. Effectiveness of two fluoroquinolones for the treatment of chronic respiratory disease outbreak in broilers. *British Poultry Science* 39(1):42-46
- Talebiyan R, Kheradmand M, Khamesipour F & Rabiee-Faradonbeh M. 2014. Multiple antimicrobial resistance of *Escherichia coli* isolated from chickens in Iran. *Vet Med Int Article ID 491418*: 1-4

- Timoney JF, Gillespie JH, Scott FW & Barlough JE. 1988. Hagan and Bruner's microbiology and infectious diseases of domestic animals: With reference to etiology, epizootiology, pathogenesis, immunity, diagnosis, and antimicrobial susceptibility. Cornell University Press
- Zimbro MJ, Power DA, Miller SM, Wilson GE & Johnson JA. 2009. Difco & BBL manual. Manual of Microbiological Culture Media (2nd edn). Becton, Dickinson and Company, Maryland, USA